

Patient details

Full name

DoB

Unit number

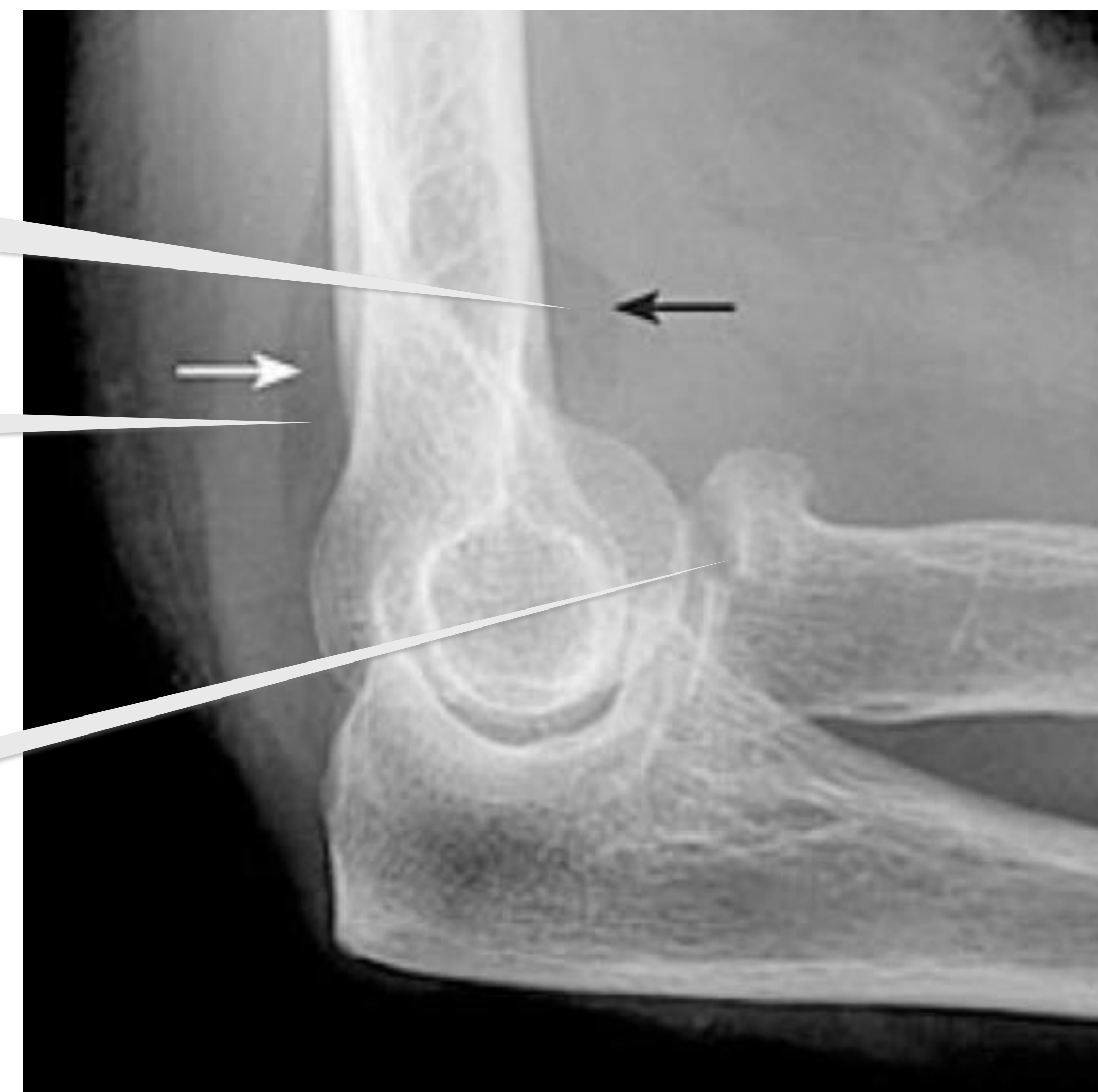
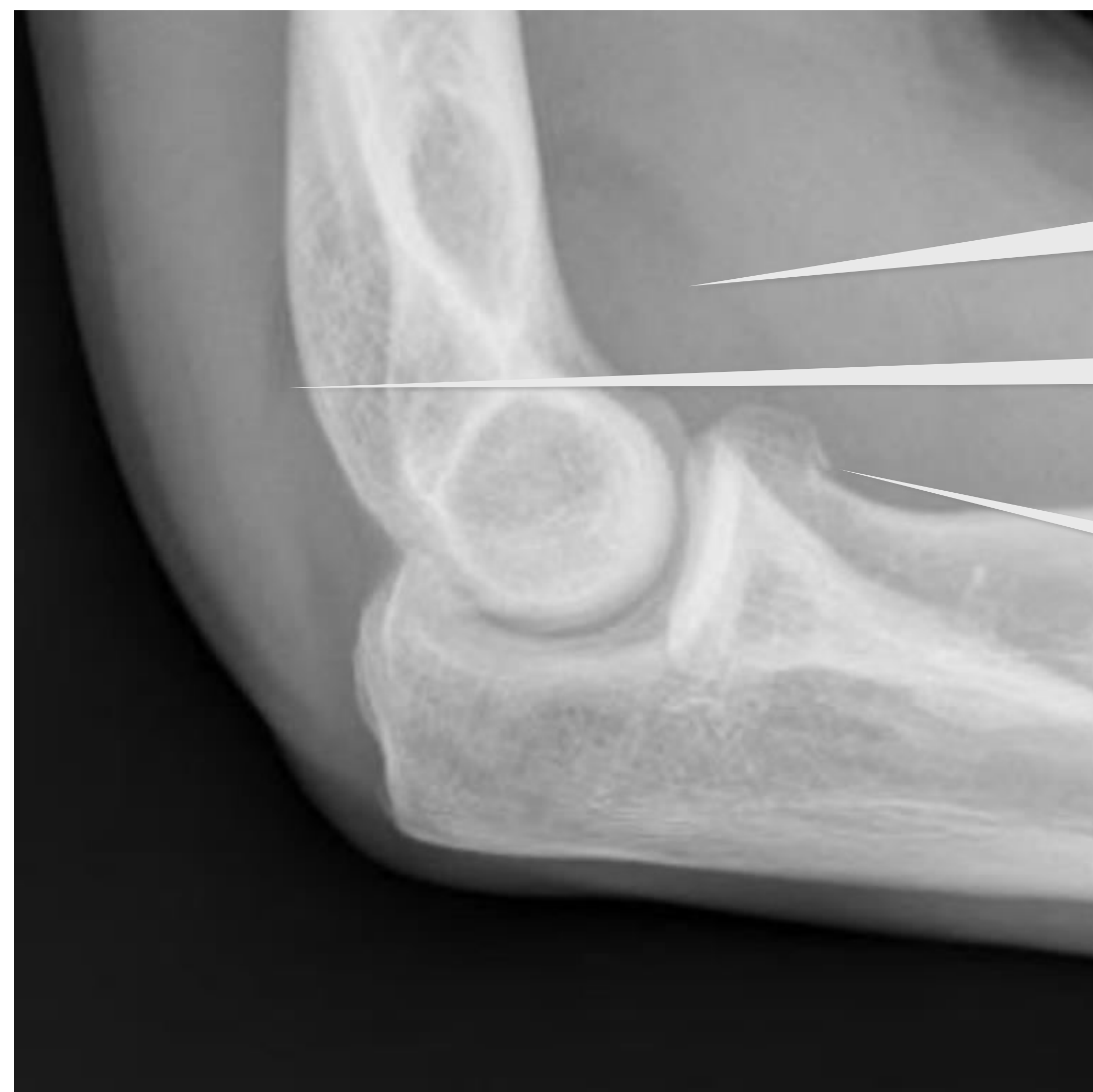(use sticker if available)

Radial head fracture

To be used when radiographs show fracture, posterior fat pad or sail sign in patients aged 16 years and over

Disclaimer:

This is a clinical template; clinicians should always use judgement when managing individual patients



Raised anterior fat pad (sail sign)

Posterior fat pad (any)

Undisplaced fracture

Displaced fracture

Ensure documentation of

- Hand dominance
- Occupation/hobbies
- Range of movement (pronation/supination & flexion/extension)
- Neurovascular status (Rock Paper Scissors OK)

Is fracture displaced (see pictures above)?

N

Y

Manage as appropriate
Discuss with ED senior as needed (record name below)

N

Is fracture **BOTH** isolated **AND** unilateral?

Y

- Fit patient with poly sling
- Give them the [Radial head fracture PIL](#) and talk them through the management plan; including that follow-up will not be needed
- Place **fracture clinic sticker** on the front sheet of the ED record
- Complete fracture clinic ICE referral, print and insert into ED record

Will discharge be safe?

Y

N

Discharge

Admit to appropriate team depending on presence or absence of additional injuries or illness (e.g. EDU/EFU/AFU)

E-referral to orthopaedic team

Assessment was carried out by

Print name

Signature

Position

Date

Time completed